

Case Report

EXTREME HYPERLEUKOCYTOSIS IN AN EXTREMELY PRETERM INFANT

Lucio E. Ortega-Martinez^{1*}, Saleena Ramzanali¹, Perla Mora, Samer-Zaid Kaylani¹, Olubukunola Adesanya¹

Author information: Department of Pediatrics, Texas Tech University Health Sciences Center, Amarillo, Texas, USA

Received: 06-24-2022; Accepted: 07-05-2022; Published: 07-07-2022.

Abstract: We present this rare case of hyperleukocytosis in an extremely premature infant to highlight the importance of a thorough investigation, including sources of infection in the mother's history and placental pathology report, to determine the cause of hyperleukocytosis in preterm neonates.

An extremely preterm male infant at 25.1 weeks gestation developed extreme hyperleukocytosis on Day of life (DOL) 3, with a peak white blood cell (WBC) count of $146.5 \times 10^9/L$ on DOL 5. The patient was admitted to the NICU due to prematurity, respiratory distress, and suspected sepsis. Laboratory analyses were done to exclude sepsis with a leukemoid-like reaction, Down syndrome by karyotype, leukemia, or other myeloproliferative disorders. After a meticulous investigation and ruling out the most common causes of leukocytosis in preterm neonates, we concluded that the hyperleukocytosis in this extreme premature infant was likely caused by maternal chorioamnionitis and fetal funisitis as reported by placental pathology.

Keywords: leukocytosis, premature, chorioamnionitis, funisitis, leukemoid reaction.

INTRODUCTION White blood cells (WBC, or Leucocytes) have normal laboratory values ranging from $9.0-30.0 \times 10^9/L$ in neonates [1]. *Leukocytosis* is defined as an increase in the total number of WBC $> 30.0 \times 10^9/L$ in neonates. Leukocytosis can result from many reasons, such as inflammatory, infectious, malignancy, physiologic, or stress responses [2].

Hyperleukocytosis refers to an increase in the total WBC $>50.0 \times 10^9/L$ [1] and can be seen in myeloproliferative disorders, leukemias, and leukocyte adhesion deficiency disorders [2]. Leukocytosis in preterm infants is common; however, extreme hyperleukocytosis of $>100.0 \times 10^9/L$ is rare and has not often been described [3].

Hyperleukocytosis can be a diagnostic dilemma for a clinical team and can lead to a long series of investigations and laboratory studies to determine the cause. Current literature shows limited data on hyperleukocytosis in

preterm infants. Few case series were done outside of the United States, and there has been little to no report of hyperleukocytosis in preterm infants in the United States.

CASE PRESENTATION An extremely preterm male infant was delivered by emergency cesarean section due to preterm labor (PTL) at 25- and 1/7-weeks' gestation to a 27-year-old Gravida 1, Para 1, Hispanic woman. The preterm male infant developed severe leukocytosis on the day of life (DOL) 3. The mother presented to the labor and delivery service in PTL with a bulging amniotic sac with a history of breech presentation and spontaneous prolonged premature rupture of membranes over 35 hours. The mother had regular antenatal checkups starting at eight weeks of gestation. Prenatal laboratory analysis showed; O positive, antibody screen negative, Group B Streptococcus (GBS) positive adequately treated, Rubella Immune, Rapid plasma regain/Human immunodeficiency virus/Gonococcal/Chlamydia/Hepatitis B surface Antigen tests, all negative. The mother received antenatal magnesium sulfate for prematurity neuroprotection, two doses of betamethasone for fetal lung maturity, and three doses of Ampicillin for GBS-positive status treatment. The pregnancy was further complicated by bacterial vaginosis and was treated with Metronidazole but no other

*Corresponding author: Lucio E. Ortega-Martinez, Department of Pediatrics, School of Medicine, Texas Tech University Health Sciences Center at Amarillo, 1400 S Coulter St Ste 1500 Amarillo, TX, USA, 79106. Phone (806) 414-9800. Fax (806) 354-5689.

significant maternal medical history. Negative maternal history of alcohol, tobacco, or recreational drugs. The patient characteristics are presented in Table 1.

Gender	Male
Gestational age	25 weeks 1 day
Delivery route	C-section
Birth weight (g)	930
Apgar scores	2/2/6/7
Antenatal steroids	Yes
Respiratory distress syndrome	Yes, Requiring Intubation in the OR
Pathology placenta	Acute chorioamnionitis with Funisitis
COVID-19*	Negative
Cultures	Negative

Table 1. Patient characteristics.

* (Antigen PCR test and IgG, IgM Antibodies test); (OR-operating room).

The neonate was admitted to the Neonatal intensive care unit (NICU) due to prematurity, respiratory distress, and sepsis evaluation. Admission chest x-ray was consistent with moderate respiratory distress syndrome (RDS). The infant's initial blood gas was unremarkable. Laboratory evaluation and sepsis workup was done (Table 2). Sepsis screening laboratory analyses were reassuring, except for complete blood count (CBC).

On DOL 3, WBC increased to leukocytosis, so ampicillin and gentamicin were started. The antibiotics were then changed to ampicillin and ceftazidime to avoid the nephrotoxic effect of long-term use of gentamicin. On DOL 5, WBC reached their maximum level of $146.5 \times 10^9/L$ (Table 2 and Figure 1) with an LDH of 1220 units/L and a normal uric acid level of 3.8 mg/dL. The antibiotics were changed again, and the patient was started on meropenem due to suspected necrotizing enterocolitis (NEC) on DOL 10. The infant was treated for ten days of IV antibiotics for suspected septicemia due to hyperleukocytosis. Obtained CSF, urine, and blood

cultures were followed until completion but returned negative.

Hematology/Oncology was consulted, and they suspected a transient myeloproliferative disorder or exaggerated reactive leukocytosis. Fluorescent in-situ hybridization (FISH) tests for trisomy 13, 18, 21, karyotype, and chromosomal microarray analysis (CMA) were ordered. The chromosome analysis and microarray both had normal results. Hematology/Oncology ordered a peripheral blood smear, showing high WBC, with majorly increased myeloid precursors with few immature forms seen; these results looked suspicious for infection or possible Coronavirus disease 19 (COVID-19) infection, although both baby and mother were COVID-19 negatives.

Serial CBCs were done and showed resolving left shift with decreasing WBC count of $17.5 \times 10^9/L$ at DOL 14. Blood and urine cultures remained negative throughout the hyperleukocytosis period.

The patient was closely monitored for complications related to hyperleukocytosis, showing no organ dysfunction, and having normal head ultrasounds at DOL 7 and 30.

The patient responded well to supportive treatment, remained hemodynamically stable, and was successfully discharged home with family at DOL 111 with a WBC count of $8.1 \times 10^9/L$.

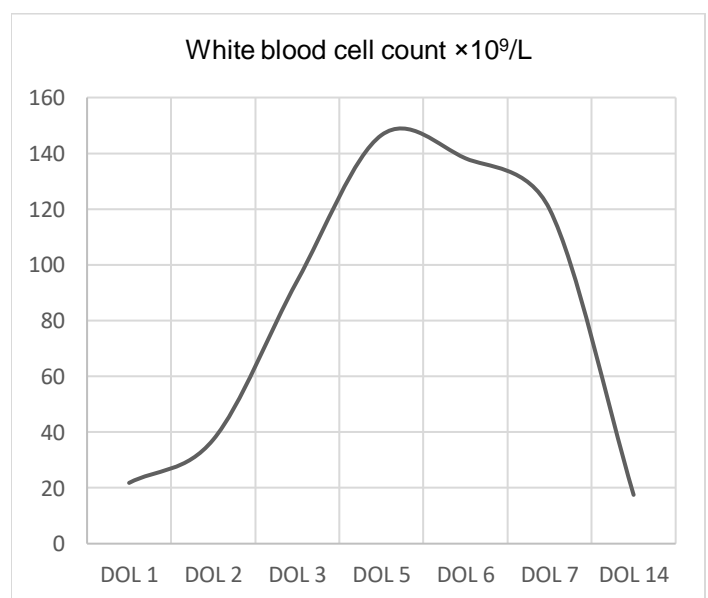


Figure 1. The course of white blood cell count (WBC), with a peak WBC of $146.5 \times 10^9/L$ on Day of life (DOL) 5.

Day of life (DOL)	1	2	3	5	6	7	14
WBC ($\times 10^9/L$)	21.8	37.3	94.3	146.5	138.2	120	17.5
Neutrophils (%)	76	52	63	84	62	52	61
Bands (%)	0	1	2	6	1	5	0
Lymphocytes (%)	14	22	6	5	6	21	19
Monocytes (%)	8	22	15	2	14	12	17
Eosinophils (%)	2	2	2	0	0	0	3
Blast (%)	N/A	N/A	3	0	0	5	0
Metamyelocytes (%)	N/A	N/A	3	1	1	2	N/A
Myelocytes (%)	N/A	N/A	3	2	16	3	N/A
Promyelocytes (%)	N/A	N/A	3	0	0	3	N/A

Table 2. Laboratory findings and parameters.

DISCUSSION Severe or extreme leukocytosis, defined as WBC greater than $100.0 \times 10^9/L$, is a rare entity in preterm infants. Leukocytosis has been associated with hematologic disorders such as myeloproliferative disease, leukemia, leukocyte adhesion deficiency, infections, or multifactorial inflammatory processes [2-4]. Hyperleukocytosis could be a medical emergency. The increased blood viscosity, secondary to high WBC count and leukocyte aggregates, results in stasis in the smaller blood vessels. This predisposes to neurological, pulmonary, or gastrointestinal complications [4]. Our patient did not develop any apparent complications of hyperleukocytosis.

Some of the processes that we must keep in mind when evaluating a patient with hyperleukocytosis include congenital leukemia (CL), leukemoid reaction, prematurity [5], a transient myeloproliferative disease with chromosomal abnormalities such as trisomy 21, perinatal infections, chorioamnionitis, sepsis, among others [4,5].

Transient myeloproliferative disease (TMD) is a complex, multistep process leading to the transient presence of blasts of megakaryocytic lineage in the peripheral blood of infants with trisomy 21. While some steps in this pathway have been elucidated, many remain unknown.

TMD arises during fetal development and hematopoiesis [6]. The incidence of TMD in Down syndrome (DS) varies depending on the screening practices and diagnostic criteria used. Reported incidence rates among infants with DS range from 10 to 30 percent [7]. Our patient's hyperleukocytosis and elevated LDH led us to consider TMD and CL.

Congenital leukemia is leukemia that develops in utero. CL is extremely rare, usually diagnosed at birth or within 1-month of life. Incidence is reported to be 1 in 5 million [8]. The doubling time of leukemic cells leads to clinically evident disease after birth or shortly after that [8]. No elevated blasts were found in our patient's blood smear and, in addition to the normal chromosomal test, prompted us to rule out CL and TMD.

A leukemoid reaction is an increase in WBC that mimics leukemia [9]. Still, it may result from various factors, including hemorrhage, toxins, infections, medications (e.g., betamethasone) [10], or any other non-leukemia cause. WBC usually returns to normal when the underlying condition is resolved [11]. The incidence of leukemoid reaction in the NICU varies from 1.3 to 15% [9]. The lack of an apparent cause for this patient's hyperleukocytosis prompted us to go back into the mother's chart to look at

the placental pathology results sent after birth. A diagnosis of a three-vessel umbilical cord with acute funisitis was made along with fetal membranes with signs of acute chorioamnionitis, membrane infarction, necrosis, and bacterial overgrowth. Placental pathology also showed preterm placental parenchyma with a parenchymal hematoma and abscess. *No placental tissue culture was done (this could have yielded the bacterial culprit).*

Funisitis is an umbilical stump's inflammation with mild drainage and erythema [12]. Funisitis and chorionic vasculitis are hallmarks of fetal inflammatory response syndrome (FIRS) [12]. FIRS is associated with the impending onset of preterm labor, an elevation of IL-6, a higher rate of neonatal morbidity, and multi-organ fetal involvement [12]. Although we did not check this patient's IL-6, there is a high suspicion that the maternal placenta was the reason behind this patient's hyperleukocytosis. There are several things to consider about the source of infection in this case. Although the patient had repetitive negative blood, urine, and CSF cultures, it is possible that the bacteria causing the infection was unable to grow on the specific culture media being used. The patient could have had another source of infection that was not investigated during his hospital stay. The decision was made to treat the infant without a documented source of infection, but there is no way to know the outcome of this patient if treatment had not been initiated.

Our patient was diagnosed with extreme hyperleukocytosis, most likely secondary to acute chorioamnionitis with funisitis in an extremely premature infant (extremely preterm is defined as <28 weeks of gestation, according to the WHO). No hyperhydration, leukapheresis, or exchange transfusion was performed. WBC level returned to normal levels (<30.0 ×10⁹/L) at DOL 14.

CONCLUSION Extreme hyperleukocytosis due to leukemoid reactions in extremely premature infants are rare and have not often been reported. This report describes an extremely premature neonate with hyperleukocytosis of >100.0 ×10⁹/L, managed with antibiotics for suspected sepsis. Based on history, physical examination, placental pathology, absence of significant anemia and thrombocytopenia, and differential WBC count, we diagnosed a leukemoid reaction due to chorioamnionitis, placenta abscess, bacterial overgrowth, and funisitis.

We present this rare case of hyperleukocytosis in an extremely premature infant to highlight the importance

of a thorough investigation, including infection source in the mother's history and placental pathology.

Disclosure:

The author declares no conflicts of interest.

REFERENCES

1. Marcadante, Karen J., and Robert Kliegman. Nelson Essentials of Pediatrics. Eighth edition. Philadelphia, PA: Elsevier, 2019. p. 565,600.
2. Parvez Y, and Aji GM. Hyperleukocytosis in newborn: a diagnosis of concern. Indian J Hematol Blood Transfus. 2014; 30(Suppl 1):131-2. doi: 10.1007/s12288-013-0286-8.
3. Jansen E, Emmen J, Mohns T, et al. Extreme hyperleucocytosis of the premature. BMJ Case Rep. 2013;2013: bcr2012008385. doi: 10.1136/bcr-2012-008385.
4. Richa J, Bansal D, Marwaha RK. Hyperleukocytosis: emergency management. Indian J Pediatr. 2013; 80(2):144-8. doi: 10.1007/s12098-012-0917-3.
5. Morag I, Dunn M, Nayot D, Shah PS. Leukocytosis in very low birth weight neonates: associated clinical factors and neonatal outcomes. J Perinatol 2008;28(10):680-4. doi: 10.1038/jp.2008.78.
6. Zipursky A. Transient leukaemia—a benign form of leukaemia in newborn infants with trisomy 21. Br J Haematol. 2003;120(6):930-8. doi: 10.1046/j.1365-2141.2003.04229.x.
7. Hitzler J, Garraus M. Transient myeloproliferative disorder of Down syndrome. In: Julie R Park, MD, ed. UpToDate, 2022. Available from: <https://www.uptodate.com/contents/transient-myeloproliferative-disorder-of-down-syndrome> (Access: 7/04/2022)
8. Shrivastava JP, Magnani KK, Tripathi L, Mangal KS. Congenital acute myeloid leukemia: A rare diagnostic enigma case report with review of literature. South Asian South Asian J Cancer. 2016;5(4):212-213. doi: 10.4103/2278-330X.195349.
9. Avabratha, K. Shreedhara, et al. Hyperleukocytosis in a neonate: A diagnostic dilemma. Indian J Med Paediatr Oncol. 2010;31(3):86-8. doi: 10.4103/0971-5851.73596.
10. Barak M, Cohen A, Herschkowitz S. Total leukocyte and neutrophil count changes associated with antenatal betamethasone administration in premature infants. Acta Paediatr.1992;81(10):760-3. doi: 10.1111/j.1651-2227.1992.tb12098.x.

11. Rice L, Jung M. Neutrophilic leukocytosis, neutropenia, monocytosis, and monocytopenia. In: Hoffman R, Benz EJ, Silberstein LE, et al, eds. *Hematology: Basic Principles and Practice*. 7th ed. Philadelphia, PA: Elsevier; 2018: chap 48.
12. Kim CJ, Romero R, Chaemsaihong P, et al. Acute chorioamnionitis and funisitis: definition, pathologic features, and clinical significance. *Am J Obstet Gynecol*. 2015;213(4 Suppl):S29-52. doi: 10.1016/j.ajog.2015.08.040.